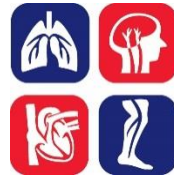

DEEP VEIN THROMBOSIS (DVT): DIAGNOSIS



OBJECTIVE:

To provide an evidenced-based approach to the evaluation of patients with a clinical suspicion of deep vein thrombosis (DVT).

BACKGROUND:

An estimated 45,000 patients in Canada are affected by DVT each year, with an incidence of approximately 1-2 cases per 1,000 persons annually. This translates into 2-4 DVTs per year in a typical, solo Canadian family practice. Since only 10-20% of patients with suspected DVT actually have the disease, a typical family practice will evaluate 20-40 patients with symptoms and/or signs suggestive of DVT each year.

The ability to rapidly and accurately assess patients for DVT is crucial. A validated diagnostic algorithm should be followed until a definitive diagnostic conclusion is reached in each patient. Treatment of DVT is crucial to prevent thrombus extension and pulmonary embolism (PE), and should often be started even prior to confirmation of DVT presence [see Deep Vein Thrombosis (DVT): Treatment guide]. The accurate exclusion of DVT also eliminates unnecessary exposure to anticoagulants, associated with inconvenience and risk of bleeding.

DIAGNOSIS:

The diagnosis of DVT is based on:

1) Pre-test probability (clinical suspicion)

There are several formal risk models available to assess the pre-test probability of DVT. The Wells Score is the most widely used (see **Table 1**). Physicians can also use their clinical gestalt to determine pre-test probability. The accuracy of this type of intuitive approach, however, is dependent on physician experience. Use of a structured score is encouraged.

TABLE 1: TWO-LEVEL WELLS SCORE FOR DVT DIAGNOSIS

CLINICAL FINDINGS	POINTS
Paralysis, paresis or recent orthopedic casting of lower extremity	1
Bedridden >3 days recently or major surgery within past 12 weeks	1
Localized tenderness of the deep veins	1

Swelling of entire leg	1
Calf swelling 3 cm greater than other leg (measured 10 cm below the tibial tuberosity)	1
Pitting edema greater in the symptomatic leg	1
Non-varicose collateral superficial veins	1
Active cancer or cancer treated within 6 months	1
Previously documented DVT	1
Alternative diagnosis at least as likely as DVT (Baker's cyst, cellulitis, muscle damage, superficial vein thrombosis, post-thrombotic syndrome, inguinal lymphadenopathy, extrinsic venous compression)	-2

WELLS SCORE	PROBABILITY OF DVT	STRATA
<2	6%	Unlikely
≥2	28%	Likely

2) Venous Compression Ultrasound (CUS)

Proximal leg CUS examines the compressibility of the femoral and popliteal veins. Failure to demonstrate full compressibility of a proximal vein in a patient without prior DVT is highly diagnostic of DVT. Because distal thrombosis may extend proximally in ~20% of cases, an initial negative proximal CUS should be repeated after 5-7 days in patients with a high clinical suspicion of DVT. Although international guidelines recommend against distal vein imaging (to reduce detection and often unnecessary treatment of distal DVT), some centres routinely perform whole-leg CUS to eliminate the need for serial studies. While a technically-adequate, negative whole leg CUS excludes DVT, the finding of an isolated calf DVT leads to some uncertainty about management (i.e. whether to treat or to perform serial CUS to look for extension). In general, clinicians may choose to treat if the patient is very symptomatic, bleed risk is low and/or probability of thrombus extension is high [see Deep Vein Thrombosis (DVT): Treatment guide].

3) D-Dimer

D-Dimer is a sensitive but non-specific marker of thrombosis. Although D-dimer is elevated in patients with DVT, it is also elevated in a variety of other common conditions including, but not limited to, inflammatory diseases, malignancy, pregnancy, surgery, trauma, and advanced age. This renders the test useful to help rule out DVT when negative, but of no diagnostic value when positive. Although there are several D-dimer assays available, those that are typically used in Canada are all highly sensitive assays (sensitivity of greater than 90%) and can be used in combination with an unlikely pretest probability (Wells or clinical gestalt) to exclude DVT. However, clinicians should check with their laboratory to confirm the status of the D-dimer assay used. Realistically, community-based physicians are unlikely to receive timely D-dimer results from outside laboratories and may not be able to use strategies involving these tests. Alternative management approaches include diagnostic

algorithms incorporating pre-test probability assessment and CUS (outlined below) or direct referral to an Emergency Department or Thrombosis Clinic.

DIAGNOSTIC STRATEGY:

Patients with suspected DVT should first undergo a history and physical exam focused on the components of the Wells Score, as well as symptoms and signs of PE [see Pulmonary Embolism (PE) Diagnosis guide]. Patients with an unlikely pre-test probability for DVT should then undergo D-dimer testing with management as outlined in **Figure 1** below. With a likely pre-test probability, proximal CUS is the recommended first-line test. Those with a negative proximal CUS should undergo D-dimer testing or repeat CUS in 5-7 days to eliminate the possibility of a missed distal DVT that might extend proximally.

In jurisdictions where CUS is readily available in a timely manner and where D-dimer turnaround times are long, proceeding directly to proximal CUS for all patients suspected of a DVT is a reasonable but more costly strategy. With this approach, a negative proximal CUS and unlikely pre-test probability excludes DVT, while patients with a likely pre-test probability and negative proximal CUS should have CUS repeated in 5-7 days.

If whole leg CUS is undertaken and isolated distal DVT is detected, anticoagulation should be offered if severe symptoms are present or if the risk of proximal extension is high. Alternatively, patients may be followed with serial CUS over a 1 - 2 week period, after which time extension is unlikely. Those unlikely or unable to return for follow-up testing should generally be treated. Risk factors for proximal extension of a distal DVT include: positive D-dimer, calf DVT that is extensive or close to the proximal veins, absence of a reversible provoking risk factor, cancer, previous history of venous thromboembolism, lower extremity immobilization (e.g. plaster casting, neuromuscular disease), and in-patient status.

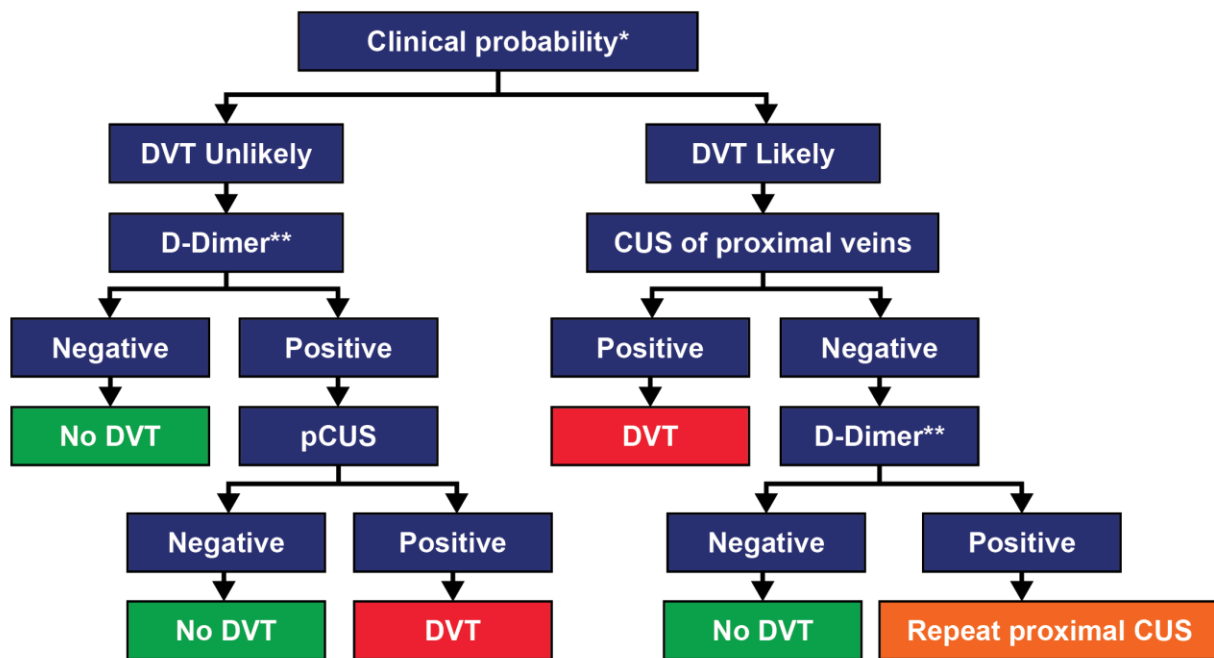


Figure 1. Suggested diagnostic strategy for patients with suspected DVT. *Clinical probability can be assessed by Wells score or experienced clinician gestalt. **D-dimer should be measured using a highly sensitive assay to rule out DVT using this algorithm; if D-dimer testing is not available, CUS should be performed in all patients; a negative CUS and unlikely pre-test probability excludes DVT, while patients with a likely pre-test probability and negative CUS should have CUS repeated in 5-7 days. pCUS, proximal compression ultrasound.

SPECIAL CONSIDERATIONS:

Timing of diagnostic testing:

Testing should be undertaken as quickly as possible. However, if there will be a significant delay, patients with a moderate/high or likely pre-test probability of DVT should receive a rapidly acting anticoagulant (e.g. low-molecular-weight heparin or a direct oral anticoagulant) until testing is performed, unless they are at high risk of bleeding or have another contraindication to anticoagulant therapy.

Suspected recurrent DVT:

In the case of suspected recurrent ipsilateral DVT, CUS can be problematic because residual compression abnormalities are often present from the previous DVT. In such cases, it is important to compare CUS results with those from prior examinations. Recurrent DVT can only be definitively diagnosed with evidence of new thrombosis, including non-compressibility in previously normal venous segments or increases of at least 4 mm in compression diameter from prior studies. A negative D-dimer may make the diagnosis of recurrence less likely and may be helpful when no prior CUS studies are available for comparison. Consultation with an expert in the field may be helpful in this setting and especially when no prior CUS is available for comparison.

Upper extremity DVT (UEDVT):

[See also Central Venous Catheter-Related Deep Vein Thrombosis guide]

UEDVT is uncommon with an annual incidence of approximately 3/100,000 persons. Most patients with UEDVT have risk factors including: central venous catheter, recent pacemaker or malignancy. Spontaneous UEDVT is often related to sudden physical effort and narrowing of the thoracic outlet (Paget-Schroetter syndrome, thoracic outlet syndrome). Clinical manifestations include acute and chronic arm pain, swelling, discoloration, and dilated collateral veins over the arm, neck or upper chest.

Combined CUS and color Doppler flow studies generally are used to evaluate patients with suspected UEDVT. If the initial US is negative, the diagnosis can be considered excluded unless the clinical suspicion is high. If the clinical suspicion remains high, further testing with D-dimer (with additional imaging if positive), repeat CUS, or traditional contrast venography, CT venography, or MRI is suggested. Although one study reported that the combination of an unlikely pre-test probability (using the Constans Clinical Decision Score) and negative high

sensitivity D-dimer was able to exclude UEDVT in a small proportion of patients, pre-test probability scores and D-dimer testing have not been well validated for suspected UEDVT.

Pediatrics:

Diagnosis of DVT is initiated with a CUS. While CUS testing is non-invasive, it may not be accurate for the upper extremity venous system and there have been few studies in the lower venous system. If the clinical suspicion is high for DVT with a negative CUS, the use of magnetic resonance imaging or computed tomography may be considered. Studies using pre-test likelihood or D-dimer as part of a diagnostic plan have not been completed in pediatric patients.

Suspected DVT in pregnancy:

[See also Diagnosis of DVT and PE in Pregnancy guide]

If DVT is diagnosed during pregnancy, it is found in the left leg in 80% of cases; additionally, there is a high frequency of iliofemoral (64%) and isolated iliac vein (17%) thrombosis in this population. Standard ultrasound strategies may be less sensitive in pregnant women because they do not consider the increased frequency of pelvic and iliac vein thrombosis seen during pregnancy and because of the poor sensitivity of standard US for DVT restricted to these areas. Structured DVT prediction rules have not been well validated for use during pregnancy and the usual recommended D-dimer cut-points are of limited utility in this population.

Pregnant women with suspected DVT should undergo CUS of the deep venous system from the common femoral to the popliteal vein, along with Doppler examination of the external iliac vein. If the initial study is negative, repeat testing should be performed at least once over the next 3-7 days. Depending on local availability and expertise, MRI can be used to confirm abnormalities restricted to the iliac vein.

OTHER RELEVANT THROMBOSIS CANADA CLINICAL GUIDES:

- Central Venous Catheter-Related Venous Thrombosis
- Deep Venous Thrombosis (DVT): Treatment
- Pregnancy: Diagnosis of DVT and PE
- Pulmonary Embolism (PE): Diagnosis

REFERENCES:

Bates SM, et al. Diagnosis of DVT: Antithrombotic Therapy and Prevention of Thrombosis, 9th ed: American College of Chest Physicians Evidence-Based Clinical Practice Guidelines. Chest 2012;141(2 Suppl):e351S-418S.

Chan WS, et al. Venous thromboembolism and antithrombotic therapy in pregnancy: SOGC Clinical Practice Guideline. J Obstet Gynaecol Can 2014;36(6):527-553.

Kleinjan A, et al. Safety and feasibility of a diagnostic algorithm combining clinical probability, D-dimer testing, and ultrasonography for suspected upper extremity deep venous thrombosis: a prospective management study. *Ann Intern Med* 2014;160(7):451-457.

Monagle P, et al. Antithrombotic therapy in neonates and children: Antithrombotic Therapy and Prevention of Thrombosis, 9th ed: American College of Chest Physicians Evidence-Based Clinical Practice Guidelines. *Chest* 2012;141(2 Suppl):e737S-801S.

National Institute for Health and Clinical Excellence. Venous Thromboembolic Diseases: Diagnosis, Management and Thrombophilia Testing.; 2015 November:
<http://www.nice.org.uk/guidance/cg144/>

Date of Version: 2018April11

Please note that the information contained herein is not to be interpreted as an alternative to medical advice from your doctor or other professional healthcare provider. If you have any specific questions about any medical matter, you should consult your doctor or other professional healthcare providers, and as such you should never delay seeking medical advice, disregard medical advice or discontinue medical treatment because of the information contained herein.