



Objective:

To provide an evidence-based approach to the diagnosis and management of patients presenting with superficial vein thrombosis (SVT).

Background:

Superficial thrombophlebitis or superficial vein thrombosis (SVT) results from thrombus formation in a superficial vein with associated inflammation of the vessel wall. SVT is most often observed in the lower extremities, with greater saphenous vein (GSV) involvement in 60-80% of affected individuals. SVT is 6-fold more common than venous thromboembolism (VTE) with a yearly incidence rate of 0.64%.

Risk factors for SVT are similar to those for deep vein thrombosis (DVT) and pulmonary embolism (PE) and include active malignancy or cancer therapy, surgery, venous procedures, trauma/injury, immobilization, obesity, estrogen use/pregnancy (particularly in the first month postpartum), a personal or family history of VTE, and inherited thrombophilia. In addition, SVT often occurs in the presence of varicose veins (present in up to 80% of SVT patients) and, in the upper extremities, is usually associated with intravenous catheters. SVT is a risk factor for concomitant and future VTE.

Diagnosis:

At diagnosis, approximately 25% of patients with SVT are found to have concomitant VTE. The diagnosis of SVT can be made clinically, based on the presence of characteristic signs and symptoms including erythema, warmth and tenderness along a palpable cord. Compression ultrasound (CUS) is suggested in most cases to confirm the presence of SVT, rule out DVT, and delineate the length of the thrombus and proximity to the saphenofemoral junction (SFJ) or saphenopopliteal junction (SPJ), where the GSV and small saphenous vein join the deep veins, respectively. Details regarding these parameters should be sought from the radiologist when not included in the ultrasound report.

CUS should be considered in patients with clinically diagnosed SVT, particularly those with symptoms above the knee or located close to the popliteal fossa, in those with symptoms suggestive of DVT and in patients with VTE risk factors. Patients with below the knee SVT restricted to a varicose vein without additional VTE risk factors may not require CUS assessment.

Treatment of SVT:

General measures:

- As approximately 4% of patients with SVT will have a concomitant PE, all patients should be assessed for a history of PE symptoms (e.g. dyspnea, pleuritic chest pain, hemoptysis) and investigated accordingly [[See Clinical Guide Pulmonary Embolism \(PE\): Diagnosis](#)].
- Patients with upper extremity SVT associated with vein cannulation or IV catheters should be assessed for signs of infection (e.g. fever, purulent discharge at insertion site).

Approach to treatment

Once SVT is diagnosed, treatment will depend on whether or not a concomitant DVT is identified and on the extent and most proximal location of the SVT (see **Figure 1** for management algorithm). Antibiotic therapy is generally not indicated unless there are signs of infection.

- Patients in whom a **concomitant DVT** is identified should be managed with **therapeutic anticoagulation** [see [Clinical Guide Deep Vein Thrombosis \(DVT\): Treatment](#)].
- Isolated SVT which extends to **within 3 cm of the SFJ or SPJ** is associated with a high risk of progression into the deep venous system. These patients should also receive **therapeutic doses of anticoagulation** for 3 months [see [Clinical Guide Deep Vein Thrombosis \(DVT\): Treatment](#)].
- Isolated SVT **≥5 cm in length** located >3 cm from the SFJ should receive **prophylactic doses of fondaparinux (2.5 mg SC daily) or rivaroxaban (10 mg PO daily) or prophylactic/intermediate doses of LMWH (see Table 1)** for 45 days. Patients can also receive topical Nonsteroidal Anti-Inflammatory Drugs (NSAIDs) and/or compression therapy for symptomatic relief in conjunction with anticoagulation.
- Isolated SVT <5 cm in length located >3 cm from the SFJ/SPJ can be treated with oral or topical NSAIDs, compresses (warm or cool), and elevation for symptomatic relief. Compression stockings of appropriate length and tension can be considered if tolerable and no contraindications exist (e.g. known peripheral arterial disease). In patients with isolated SVT <5 cm in length located >3 cm from the deep system with severe symptoms or risk factors for extension (prior history of DVT/PE or SVT, cancer, pregnancy, hormonal therapy, recent surgery or trauma), treatment with prophylactic doses of fondaparinux (2.5 mg SC daily), prophylactic doses of rivaroxaban (10 mg PO daily) or prophylactic/intermediate doses of LMWH (**see Table 1**) for up to 45 days can be considered.
- SVT associated with IV cannulation is not generally treated with anticoagulation. Supportive measures such as warm compresses and topical NSAIDs can be considered for symptom relief.

Special Populations:

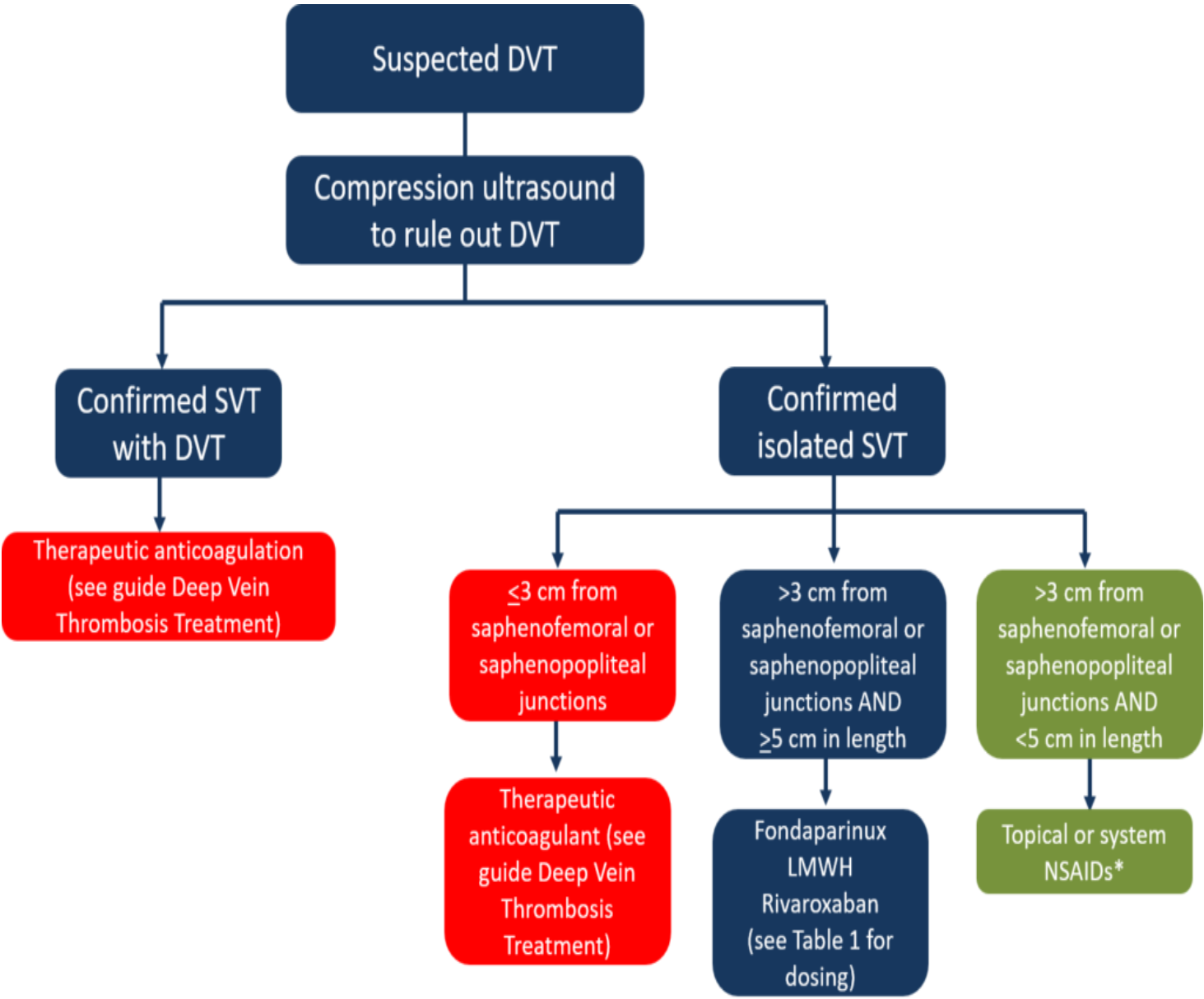
Pregnancy

No randomized studies have assessed the management of SVT during pregnancy. Guideline recommendations differ and include prophylactic or intermediate doses of LMWH for a fixed period (1 to 6 weeks) or throughout pregnancy and the postpartum period in pregnant women with SVT that is bilateral, symptomatic, ≤5 cm from the deep venous system or ≥5 cm in length. If no treatment is administered, clinical follow-up and repeat CUS is recommended within 7 to 10 days. Warfarin and DOACs are contraindicated in pregnancy as these medications can cross the placenta [see [Clinical Guide Pregnancy: Venous Thromboembolism Treatment](#)].

Pediatrics

Data regarding the management of SVT in this population are very limited. If possible, pediatric hematologists with experience in thromboembolism should manage children with or at risk for SVT. When this is not possible, a combination of a neonatologist/pediatrician and an adult hematologist, supported by consultation with an experienced pediatric hematologist, should manage these children.

Figure 1: Approach to management of SVT. DVT, deep vein thrombosis; NSAID, non-steroidal anti-inflammatory; LMWH, low molecular weight heparin



* Prophylactic/intermediate dosing anticoagulation is reasonable for severe symptoms or with risk factors. If not treating or if using topical NSAIDs, monitor for extension with serial U/S

DVT, deep vein thrombosis; **NSAID**, non-steroidal anti-inflammatory; **LMWH**, low molecular weight heparin

Table 1: Treatment Options for SVT >3cm from SFJ and ≥5 cm in Length

| Drug Class | Suggested dosing | Duration of treatment |
|------------|------------------|-----------------------|
|------------|------------------|-----------------------|

| | | |
|-----------------------|---------------------------------------------------------------------------------------------|-----------|
| LMWH | Dalteparin 5,000-10,000 units SC daily | 45 days |
| | Enoxaparin 40-80 mg SC daily | |
| | Nadroparin 2,850-5,700 units SC daily | |
| | Tinzaparin 4,500-10,000 units SC daily | |
| Fondaparinux | 2.5 mg SC daily | 45 days |
| Rivaroxaban | 10 mg PO daily | 45 days |
| Oral NSAIDs | Ibuprofen 400 mg PO TID | |
| | Naproxen 500 mg PO BID | 7-14 days |
| Topical NSAIDs | Topical diclofenac [Voltaren Emugel®] apply 2 to 4 g to affected area 3 or 4 times daily | 7-14 days |

* Patients should be treated with therapeutic anticoagulation if they have concomitant DVT and/or have isolated SVT within 3cm of the deep system (i.e. SFJ, SPJ). Choice of anticoagulant will be determined based on local availability, physician familiarity, and patient coverage, values, and preferences.

Other Relevant Thrombosis Canada Clinical Guides:

- [Deep vein thrombosis \(DVT\): Diagnosis](#)
- [Deep vein thrombosis \(DVT\): Treatment](#)
- [Pulmonary embolism \(PE\): Diagnosis](#)
- [Pregnancy: Venous Thromboembolism Treatment](#)
- [Rivaroxaban \(Xarelto®\)](#)
- [Unfractionated Heparin, Low Molecular Weight Heparin and Fondaparinux](#)

References:

Bates S, et al. American Society of Hematology (ASH) Guidelines for Management of Venous Thromboembolism in the Context of Pregnancy. *Blood Advances*. 2018;2:3317-3359.

Beyer-Westendorf J, et al. SURPRISE investigators. Prevention of thromboembolic complications in patients with superficial-vein thrombosis given rivaroxaban or fondaparinux: the open-label, randomised, non-inferiority SURPRISE phase 3b trial. *Lancet Haematol*. 2017;4(3):e105-e113.

Decousus H, et al. Fondaparinux for the treatment of superficial-vein thrombosis in the legs. *New Engl J Med*. 2010;363(13):1222-1232.

Decousus H, et al. Superficial venous thrombosis and venous thromboembolism: a large, prospective epidemiologic study. *Annals Inter Med*. 2010;152(4):218-224.

Di Minno MN, et al. Prevalence of deep vein thrombosis and pulmonary embolism in patients with superficial vein thrombosis: a systematic review and meta-analysis. *J ThrombHaemost*. 2016;14:964-972.

Di Nisio M, Wichers I, Middeldorp S. Treatment of lower extremity superficial thrombophlebitis. *JAMA*. 2018;320(22):2367-2368.

Duffett L, et al. Treatment of superficial vein thrombosis: a systematic review and meta-analysis. *Thrombosis Haemostasis*. 2019;119:479-489.

Frappe P, et al. Annual diagnosis rate of superficial vein thrombosis of the lower limbs: the STEPH community-based study. *J Thromb Haemostasis*. 2014;12:831-838.

Kearon C, et al. Antithrombotic therapy for VTE disease: Antithrombotic Therapy and Prevention of Thrombosis, 9th ed: American College of Chest Physicians Evidence-Based Clinical Practice Guidelines. *Chest*. 2012;141(Suppl 2):e419S-e494S.

Scott G, et al. Superficial vein thrombosis: a current approach to management. *Br J Haematol*. 2015;168:639-645.

Tait C, et al. Guidelines on the investigation and management of venous thrombosis at unusual site. *Br J Haematol*. 2012;159:28-38.

Van Langevelde K, et al. Increased risk of venous thrombosis in persons with clinically diagnosed superficial vein thrombosis: results from the MEGA study. *Blood*. 2011;118(15):4239-4241.

Date of version: 02September2022

Please note that the information contained herein is not to be interpreted as an alternative to medical advice from your doctor or other professional healthcare provider. If you have any specific questions about any medical matter, you should consult your doctor or other professional healthcare providers, and as such you should never delay seeking medical advice, disregard medical advice or discontinue medical treatment because of the information contained herein.