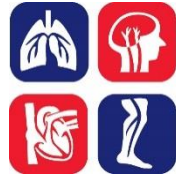

PULMONARY EMBOLISM (PE): DIAGNOSIS



OBJECTIVE:

To provide a diagnostic approach to patients with suspected acute pulmonary embolism (PE).

BACKGROUND:

Venous thromboembolism (VTE), which comprises deep vein thrombosis (DVT) and pulmonary embolism (PE), is a common disease, affecting approximately 1-2 in 1,000 adults per year. The diagnosis of PE has increased significantly since the advent of computed tomography pulmonary angiography (CTPA) with its widespread availability and enhanced sensitivity. The majority of PE originates in the proximal deep veins of the leg, despite the observation that only 25-50% of patients with PE have clinically-evident DVT at the time of PE diagnosis. While active malignancy, surgery (especially orthopedic), hospitalization, air travel >8 hours, and hormone use/pregnancy are common transient provoking factors; approximately 50% of first-time PEs appear to be unprovoked.

Symptoms of PE may include sudden onset dyspnea, pleuritic chest pain and syncope. Signs of PE may include tachypnea, tachycardia, hypoxemia, hypotension, and features of right ventricular dysfunction (distended jugular veins). There may be accompanying signs and symptoms of DVT. The ECG may show right ventricular strain ($S_1Q_3T_3$, right bundle branch block and T-inversion in leads V1-V4).

Up to 10% of symptomatic PEs are fatal within the first hour of symptom onset. Independent predictors of mortality within the first few days after diagnosis of PE include hypotension (systolic blood pressure ≤ 90 mmHg), clinical right heart failure, right ventricular dilatation on CTPA/echocardiography, positive troponin, and elevated brain natriuretic peptide (BNP). Early diagnosis and treatment of PE reduces morbidity and mortality.

DIAGNOSIS OF PE:

The constellation of symptoms and signs may be suggestive of PE but do not alone have the sensitivity or specificity to rule in or rule out the diagnosis. When the diagnosis of PE is considered, the clinical stability of the patient and associated pre-test probability will dictate the diagnostic approach (see **Figure 1**).

In patients without hypotension (SBP ≥ 90 mmHg), pre-test probability can be assessed by a validated clinical prediction rule (see **Table 1**). In patients with low pretest probability of PE, further testing is not necessary if **all** clinical features/criteria in the Pulmonary Embolism Rule-out Criteria (PERC) are present (see **Table 2**).

TABLE 1: WELLS SCORE* FOR PE

VARIABLE	POINTS
Clinical symptoms and signs of DVT	3
Previous DVT or PE	1.5
Immobilization for >3 days or surgery within 4 weeks	1.5
Heart rate >100 beats/minute	1.5
Hemoptysis	1
Malignancy	1
No alternative diagnosis more likely than PE	3
Total score*	<input type="text"/>

*Total Score: PE unlikely <4.5; PE likely ≥4.5

TABLE 2: PE RULE-OUT CRITERIA (PERC) FOR PATIENTS WITH LOW PRETEST PROBABILITY FOR PE

CLINICAL CHARACTERISTIC	MEETS CRITERIA	DOES NOT MEET CRITERIA
Age <50	0	1
Initial heart rate <100 beats/min	0	1
Initial SaO ₂ >94% on room air	0	1
No unilateral leg swelling	0	1
No hemoptysis	0	1
No surgery or trauma ≤4 weeks	0	1
No history of VTE	0	1
No estrogen use	0	1

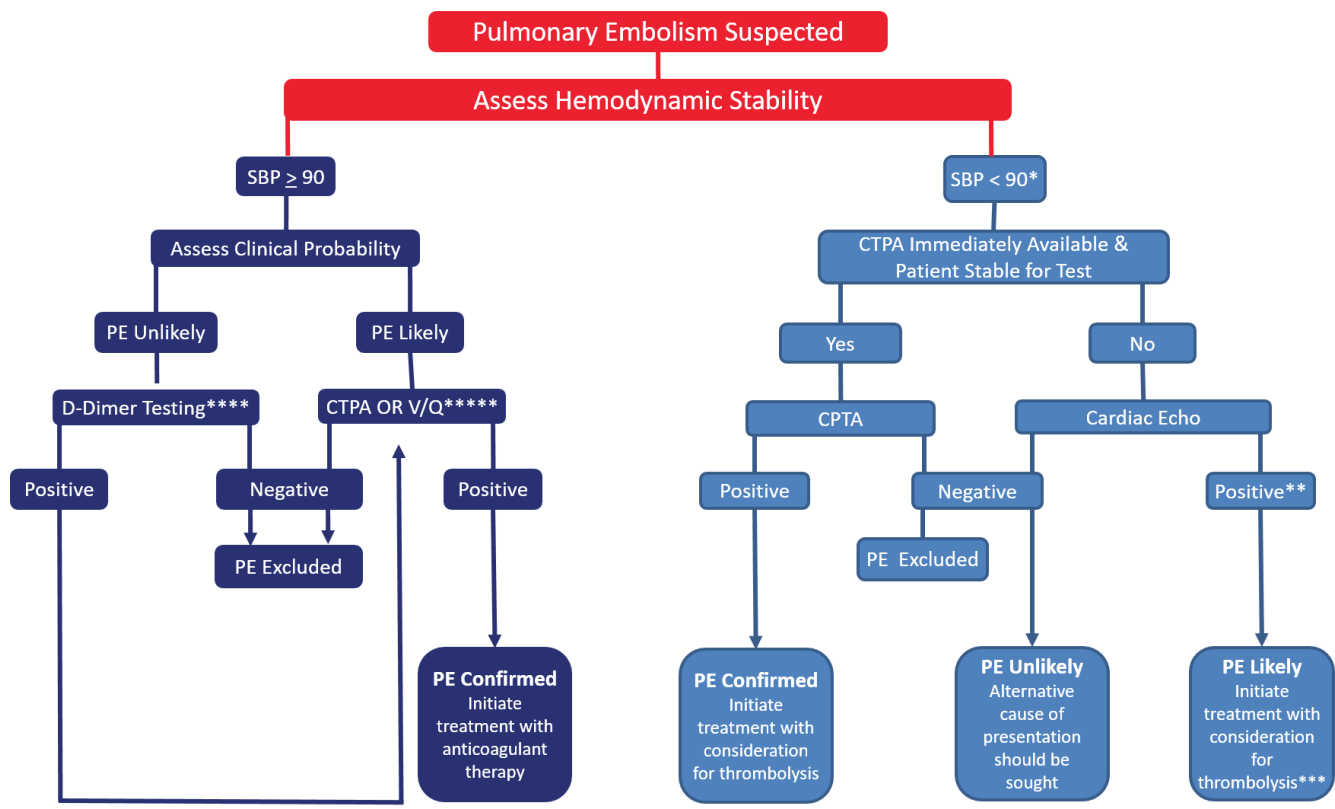
In cases with **PE unlikely pre-test probability**, a negative high sensitivity D-dimer result rules out the diagnosis of PE. However, a positive D-dimer test must be followed up with a definitive test to confirm/refute the diagnosis of PE.

Depending on the assay in use at your institution, age-adjusted D-dimer levels can increase the specificity of D-dimer testing without sacrificing sensitivity. In patients over the age of 50, a D-dimer result is considered negative if it is less than the patient age multiplied by 10 (for example, in a 76 year-old, a negative result is less than 760 µg/L). For patients under the age of 50, a D-dimer value less than 500 µg/L remains the cutoff for a negative result.

With a **PE likely pre-test probability**, there is no role for ordering a D-dimer, as the clinical likelihood of PE remains unacceptably high among those with a negative D-dimer result. Therefore, when the pre-test probability is high (PE likely), one should go directly to imaging to establish the diagnosis. **Multidetector CTPA** is widely available in Canada and is sufficiently sensitive and specific to exclude the diagnosis of PE when it is negative and to confirm it when positive. Limitations of CTPA include

substantial radiation exposure (that may increase breast cancer rates in young women), risk of contrast nephropathy, and detection of small filling defects of uncertain clinical significance. **Ventilation-perfusion (V/Q) lung scanning** has high sensitivity and specificity in patients with a normal chest X-ray who do not have significant lung disease. V/Q scanning should be considered in patients with renal insufficiency, contrast allergy, in young patients with a normal chest X-ray, and in pregnant women.

FIGURE 1: SUGGESTED DIAGNOSTIC ALGORITHM FOR SUSPECTED PULMONARY EMBOLISM



- * Consideration for thrombolysis without diagnostic test confirmation should be made if the patient has a high clinical suspicion of PE and is very unstable
- ** Features on echocardiography suggestive of massive PE include severe right ventricle (RV) dysfunction and RV/main pulmonary artery embolus
- *** If patient condition stabilizes, consideration should be given to performing CTPA to confirm the diagnosis
- **** Excluding a diagnosis of PE with a PE unlikely pre-test probability requires the use of a *highly sensitive* D-dimer assay. The use of age-specific D-dimer cut-off values, if available, appears to improve the specificity of D-dimer testing.
- ***** V/Q is the preferred test in patients with a contrast allergy or severe renal dysfunction and young patients with a normal chest X-ray and should be considered in pregnancy. If the perfusion scan is normal, further testing is not required. When the V/Q scan is neither normal nor high probability for PE (diagnostic for PE), serial compression ultrasounds (CUS) of the legs should be undertaken.

In patients with hypotension who are too unstable to undergo CTPA or if CTPA is not immediately available, an urgent echocardiogram should be obtained to look for evidence of right heart overload or embolus in the right ventricle (RV) or main pulmonary arteries. If present, and in the absence of an alternative diagnosis, treatment for PE should be initiated. However, RV dysfunction alone does not prove PE; therefore, if feasible, confirmatory evidence of VTE should be sought with further imaging (CTPA, V/Q or lower extremity compression ultrasounds [CUS]). If a hypotensive patient does not have echocardiographic features of RV dysfunction, it is unlikely that hemodynamic instability is due to massive PE (although this does not exclude smaller PE).

OTHER RELEVANT THROMBOSIS CANADA CLINICAL GUIDES:

- Deep Vein Thrombosis (DVT): Diagnosis
- Pregnancy: Diagnosis of PE and DVT
- Pulmonary Embolism: Treatment

REFERENCES:

Konstantinides SV, et al. 2014 ESC Guidelines on the diagnosis and management of acute pulmonary embolism. Eur Heart J 2014;35(43):3033-3080.

Raja AS, et al. Evaluation of patients with suspected acute pulmonary embolism: best practice advice from the Clinical Guidelines Committee of the American College of Physicians. Ann Intern Med 2015;163(9):701-711.

Righini M, et al. Age-adjusted D-dimer cutoff levels to rule out pulmonary embolism: the ADJUST-PE Study. JAMA 2014;311(11):1117-1124.

Singh B, et al. Pulmonary embolism rule-out criteria (PERC) in pulmonary embolism revisited: a systematic review and meta-analysis. Emerg Med J 2013;30(9):701-706.

Date of version: 2018Apr3

Please note that the information contained herein is not to be interpreted as an alternative to medical advice from your doctor or other professional healthcare provider. If you have any specific questions about any medical matter, you should consult your doctor or other professional healthcare providers, and as such you should never delay seeking medical advice, disregard medical advice or discontinue medical treatment because of the information contained herein.